

Sarcina ventriculi: A Rare Case of Life-Threatening Perforated Gastric Ulcer and Review of Literature

Qing Wei¹, Sixto M. Leal Jr¹, Morad Qarmali¹, Charles Mel Wilcox², Chirag R. Patel¹, Sameer Al Diffalha^{1*}

¹Department of Pathology, University of Alabama at Birmingham School of Medicine, Birmingham, USA

²Department of Medicine, Division of Gastroenterology, University of Alabama at Birmingham School of Medicine, Birmingham USA

To Cite

Wei Q, Leal SM Jr, Qarmali M, Wilcox CM, Patel CR, Al Diffalha S. *Sarcina ventriculi*: A Rare Case of Life-Threatening Perforated Gastric Ulcer and Review of Literature. J Gastric Surg 2020; 2(2): 53-56

Publication history

Received: May 10, 2020

Accepted: May 20, 2020

Article in press: May 28, 2020

Published on line: May 30, 2020

*Correspondence to

Sameer Al Diffalha, MD
NP 3552 North Pavilion,
University of Alabama
at Birmingham Hospital
Birmingham, AL 35294-6823
saldiffalha@uab.edu
Telephone: (205) 934-5749
Fax: (205) 975-5242

ABSTRACT

Sarcina ventriculi is a gram-positive anaerobic bacterium reported rarely in patients with a history of gastrointestinal surgery and delayed gastric emptying. *Sarcina* has been implicated in the development of gastric ulcers, emphysematous gastritis, and gastric perforation. So far, less than 30 cases of *Sarcina* isolated from gastric specimens have been reported, including 3 cases associated with life-threatening illness: emphysematous gastritis and gastric perforation. Herein, we report a case of a 58-year-old woman with history of gastric surgery who presented for evaluation of persistent gastric pain and incurable ulcer. She underwent total gastrectomy, and the resected stomach demonstrated a perforated ulcer with the presence of *Sarcina* microorganisms. We also report a second case of a 56-year-old woman with history of NSAID use who presented with gastric outlet obstruction. The gastric biopsy identified concurrent *Helicobacter pylori* and *Sarcina*. Given *Sarcina*'s association with emphysematous gastritis and gastric perforation, its identification on gastric biopsies should be clearly stated in pathology reports and, depending on the clinical scenario, prompt clinicians to add adjunctive antimicrobials to anti-ulcer therapeutic regimens.

Keywords:

Sarcina ventriculi; emphysematous gastritis; gastric perforation.

Background:

Sarcina ventriculi is a gram-positive, non-motile, spore-forming, anaerobic bacterial coccus with a carbohydrate fermentative metabolism.[1] Hematoxylin and Eosin (H&E) staining of gastric biopsies reveals tetrad packets of large (3µm) basophilic cuboidal or spherical microorganisms with a refractile wall.[1, 2] Molecular diagnosis is possible by polymerase chain reaction and sequencing of the 16S ribosomal RNA and pyruvate decarboxylase genes.[3]

Sarcina was first identified as a human pathogen by Goodsir in 1843.[4, 5] It is a well-described pathogen in veterinary medicine and can cause a lethal gastric bloating-like syndrome.[6] Recently it has become increasingly implicated in human gastrointestinal disease and has been described to be associated in patients with history of GI surgery and delayed gastric emptying.[1, 3] Most patients exhibit GI symptoms, with some cases of severe disease, including emphysematous gastritis and gastric perforation.[7-9] Endoscopic findings often involve retained food residue, gastric ulcers, and inflammation or erosions.[1] Herein, we present two unique cases. One of them is the third reported case of *Sarcina* associated with gastric perforation. The other presented case is the second reported case that shows rare concurrent infections of *Sarcina* and *Helicobacter pylori*.

Case 1:

A 58-year-old Caucasian woman presented to the surgical oncology clinic for evaluation of a gastric ulcer and possible total gastrectomy. She reported epigastric pain, loss of appetite, nausea, and malnutrition. She had an open gastric bypass about 20 years prior that was taken down due to development of an internal hernia. Afterwards, the patient suffered dysphagia, gastric reflux, and chronic upper GI ulcers despite antacid and *H. pylori* treatment. Leading up to the evaluation, esophagogastroduodenoscopy (EGD) revealed an ulcer of the posterior stomach wall distal to the esophagogastric anastomosis, and ulcer biopsies showed benign fragments of gastric mucosa demonstrating marked active gastritis with focal ulceration.

The patient underwent total gastrectomy, ventral hernia repair, and associated procedures. Pathologic examination of the resected stomach showed a 2.7 cm x 2.5 cm ulcer of the proximal lesser curvature with a 1-cm thickness perforation through the serosa (Figure 1a). H & E staining showed multiple foci of *Sarcina ventriculi* tetrads (Figure 1b). *Sarcina* was also identified within the gastric lumen occasionally admixed with vegetable matter, consistent with delayed gastric emptying. Organisms were identified by the granulation tissue in the ulcer base as well as on the serosal surface, which was consistent with perforation and the presence of organisms within the peritoneal cavity.

The patient's post-operative course was complicated by an anastomotic leak and polymicrobial intra-abdominal infection that required surgical revision, antibiotics (metronidazole, vancomycin, cefepime and piperacillin-tazobactam), and antifungal treatment. She recovered after an approximately one-month hospitalization and was discharged.

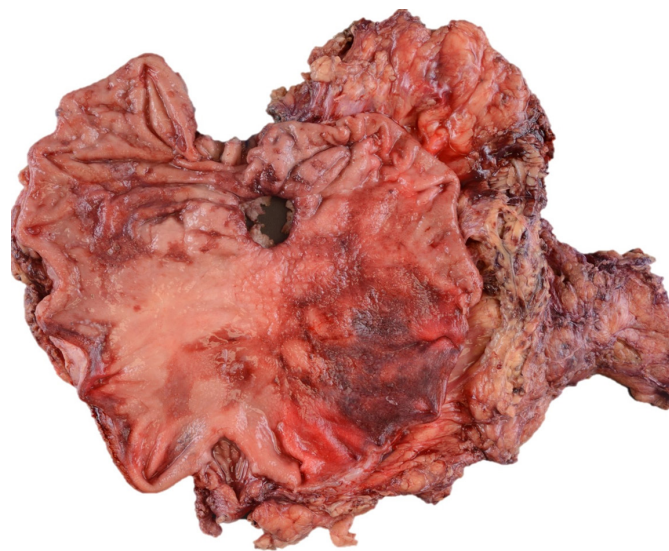

Figure 1a: Gross picture of the perforated stomach.

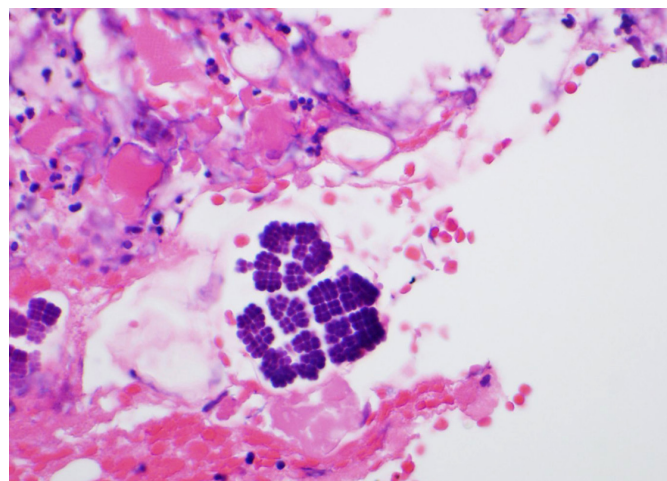


Figure 1b: The cuboid-shaped organisms were tightly packed in a tetrad formation surrounding the ulcer bed. Hematoxylin and Eosin, 40x magnification.

Case 2:

A 56-year-old woman presented with gastric outlet obstruction. She underwent four consecutive outpatient upper endoscopies at a frequency of approximately once per month. The EGDs showed an ulcer at the pre-pyloric area and a pyloric stricture, which was dilated each time. Random biopsies of the stomach during the first EGD showed chronic active gastritis, and *H. pylori* was negative by immunostaining. She started proton pump inhibitor (omeprazole 40 mg). Biopsies of the antrum taken during her second EGD showed chronic active gastritis. *Sarcina* and rare *H. pylori* microorganisms were identified on routine H&E stain (Figure 2a and Figure 2b). Similar to Case 1, *Sarcina* species were noted in the gastric lumen admixed with vegetable matter consistent with delayed gastric emptying. By the third EGD, the ulcer had healed after the treatment. By the fourth EGD, the patient was eating better without nausea or weight loss, and there was no further follow-up.

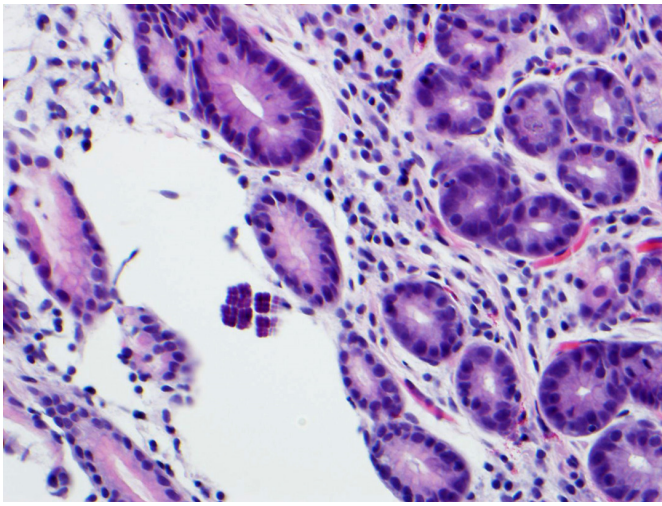


Figure 2a: *H. pylori* and *Sarcina* organisms co-exist in a gastric biopsy. The cuboid-shaped organisms were tightly packed in a tetrad formation. Hematoxylin and Eosin, 40x magnification

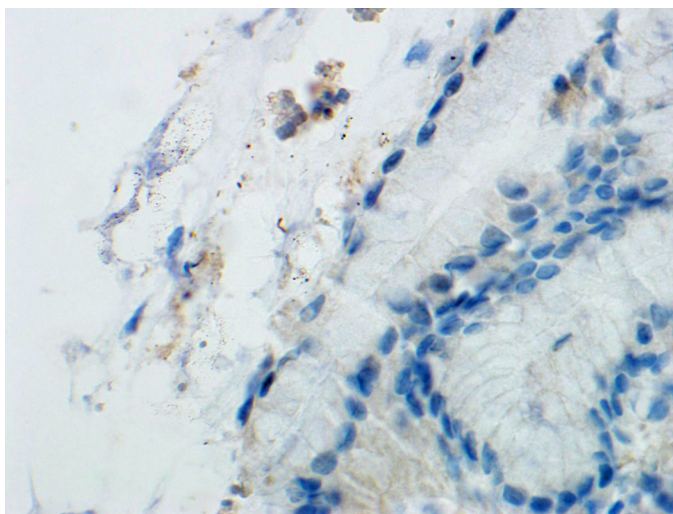


Figure 2b: *H. pylori* and *Sarcina* organisms co-exist in a gastric biopsy. *H. pylori* were detected by anti-*H. pylori* immunostain (60x magnification).

Discussion:

Sarcina is a gram-positive, anaerobic, acid-tolerant coccus. It is associated with GI surgery and exhibits a 2:1 female-to-male ratio.[1] The patients in these cases were both female; the first had a history of GI surgery, and the second had a pyloric stricture.

The pathogenic role of *Sarcina* in humans remains unclear and can be an incidental finding in gastric biopsies.[3, 10] In patients with delayed gastric emptying, retained carbohydrates and other nutrients provide a fermentative substrate for *Sarcina* overgrowth. [1] In livestock, fermentative byproducts can cause deadly emphysematous gastric bloating. In humans, fermentation byproducts may increase the risk of developing life-threatening complications, such as emphysematous gastritis and gastric perforation.

Our first case supports the idea that *Sarcina* contributes to the development of gastric ulcer perforation. The only other two reported cases of perforation were a 14-year-old male with a history of bowel reduction due to malrotation of the small intestine [8] and a 76-year-old male with acute abdominal pain who presented

in the ER and died after surgery.[9] Our patient had a history of gastric surgery and an ulcer resistant to *H. pylori* therapy. The pre-existing ulcer and delayed gastric emptying might have provided a nidus for *Sarcina* overgrowth. Morphologic findings of *Sarcina* microorganisms in both the gastric lumen and the serosa are consistent with clinically, macroscopically, and microscopically confirmed perforated gastric ulcer. As *Sarcina* can cause deadly emphysematous bloating in animals, it is possible that their association with human GI pathology is not due to direct tissue invasion but rather fermentation byproducts produced by the organism in the carbohydrate-rich gastric lumen.

Our second case demonstrates a rare example of *Sarcina* co-occurring with *H. pylori*. Only Sauter and colleagues have previously shown co-existence of *Sarcina* with *H. pylori* in two siblings.[11] Both *H. pylori* and *Sarcina* can survive in an acidic environment, and *H. pylori* infection can cause delayed gastric emptying via smooth muscle relaxation from release of leukotrienes or nitric oxide.[12] Although *H. pylori* could, in theory, be a predisposing factor in *Sarcina* infection, their rare co-occurrence may be due to eradication of *Sarcina* by anti *H. pylori* treatment.

Currently, there is no consensus on treatment regimens for *Sarcina*. [13] Published regimens leading to successful outcomes include anti-ulcer therapy and adjunctive use of metronidazole with a second antibiotic (most commonly ciprofloxacin).

It is very helpful if clinicians provide clinical information about any history of delayed gastric emptying along with the tissue that been submitted for pathology. This clinical history will alert GI pathologists to rule out the presence of *Sarcina* which is usually located near the gastric mucosal surface and has a pathognomonic tetrad morphology. To increase awareness of *Sarcina*'s association with severe disease, pathologists may include the following statement in their reports: "*Sarcina* has been reported to be present in association with emphysematous gastritis and gastric perforation."

Acknowledgements

None

Contributors

Each of the listed authors made a substantial contribution to the conception, design, and revision of this study. All authors read and approved the final manuscript.

Funding

No funding was received for this study.

Competing interests

No benefits in any form have been received or will be received from a commercial party related directly or indirectly to the subject of this article.

Availability of data and materials

Further information is available from the corresponding author on reasonable request.

Ethics approval

Not applicable

Provenance and peer review

Not commissioned; externally peer reviewed.

Open access

This is an Open Access article distributed in accordance with the Creative Commons Attribution Non-Commercial (CC BY-NC 4.0) license, which permits others to distribute, remix, adapt, build upon this work noncommercially, and license their derivative works on different terms, provided the original work is properly cited and the use is non-commercial. See: <http://creativecommons.org/licenses/by-nc/4.0/>

References

- [1] Al Rasheed MR, Senseng CG. Sarcina ventriculi: Review of the Literature. Arch Pathol Lab Med. 2016;140:1441-5.
- [2] Behzadi J, Modi RM, Goyal K, Chen W, Pfeil S. Sarcina ventriculi as an Unknown Culprit for Esophageal Stricture. ACG Case Rep J. 2017;4:e118.
- [3] Lam-Himlin D, Tsiatis AC, Montgomery E, Pai RK, Brown JA, Razavi M, et al. Sarcina organisms in the gastrointestinal tract: a clinicopathologic and molecular study. Am J Surg Pathol. 2011;35:1700-5.
- [4] Goodsir J. XXIII: History of a case in which a fluid periodically ejected from the stomach contained vegetable organisms of an undescribed form. J Nat Hist. 1843;11:125-6.
- [5] Beijerinck M. An experiment with Sarcina ventriculi. Huygens Institute-Royal Netherlands Academy of Arts and Sciences (KNAW), Proceedings. 1911;13:1910-1.
- [6] DeBey BM, Blanchard PC, Durfee PT. Abomasal bloat associated with Sarcina-like bacteria in goat kids. J Am Vet Med Assoc. 1996;209:1468-9.
- [7] Laass MW, Pargac N, Fischer R, Bernhardt H, Knoke M, Henker J. Emphysematous gastritis caused by Sarcina ventriculi. Gastrointest Endosc. 2010;72:1101-3.
- [8] Tolentino LF, Kallichanda N, Javier B, Yoshimori R, French SW. A case report of gastric perforation and peritonitis associated with opportunistic infection by Sarcina ventriculi. Laboratory Medicine. 2003;34:535-7.
- [9] Dumitru A, Aliuş C, Nica AE, Antoniac I, Gheorghişă D, Grădinaru S. Fatal outcome of gastric perforation due to infection with Sarcina spp. A case report. IDCases. 2020;19:e00711.
- [10] Haroon Al Rasheed MR, Kim GJ, Senseng C. A Rare Case of Sarcina ventriculi of the Stomach in an Asymptomatic Patient. Int J Surg Pathol. 2016;24:142-5.
- [11] Sauter JL, Nayar SK, Anders PD, D'Amico M, Butnor KJ, Wilcox RL. Co-existence of Sarcina Organisms and Helicobacter pylori Gastritis/Duodenitis in Pediatric Siblings. J Clin Anat Pathol (JCAP). 2013;1.
- [12] Zhang CL, Geng CH, Yang ZW, Li YL, Tong LQ, Gao P, et al. Changes in patients' symptoms and gastric emptying after Helicobacter pylori treatment. World J Gastroenterol. 2016;22:4585-93.
- [13] Medlicott SAC. Sarcina ventricularis complicating a patient status post vertical banded gastroplasty, a case. Journal of Gastroenterology and Hepatology Research. 2015;4:1481-4.