

# The surgical management of benign gastroduodenal perforation

Elroy Patrick Weledji<sup>1\*</sup>

<sup>1</sup>Department of Surgery, Faculty of Health Sciences, University of Buea, Buea, Cameroon

## To Cite

Weledji EP. The surgical management of benign gastroduodenal perforation. *J Gastric Surg* 2020; 2(3): 84-91

## Publication history

Received: July 30, 2020

Accepted: July 30, 2020

Article in press: August 30, 2020

Published online: August 31, 2020

## \*Correspondence to

Dr. Elroy Patrick Weledji  
Holy family Foundation,  
PO Box 126, Limbe,  
S.W.Region, Cameroon  
Telephone: +237699922144  
elroypat@yahoo.co.uk

## ABSTRACT

Gastric perforations may be spontaneous or traumatic and most of the spontaneous perforation is due to peptic ulcer disease. Improved medical management of peptic ulceration has reduced the incidence of perforation, but still remains a common cause of peritonitis. The management of perforated peptic ulcer disease is still a subject of debate. The majority of perforated peptic ulcers are caused by *Helicobacter pylori*, so apart from simple closure, definitive surgery is not usually required. Perforated peptic ulcer is an indication for operation in nearly all cases except when the patient is unfit for surgery. However, with the current advances in anaesthetic approach and with the high incidence of intra-abdominal abscesses and sepsis, non-operative management has largely been abandoned.

## Keywords:

gastroduodenal, perforation, spontaneous, management, operative.

## Background:

Gastrointestinal perforation, with leakage of alimentary contents into the peritoneal cavity, is a common surgical emergency and may have life-threatening sequelae. Gastric perforation may be spontaneous or traumatic. The causes are listed in *table 1*.

Spontaneous	Peptic ulceration Perforated carcinoma Gastric volvulus Strangulated hiatus hernia Ischaemic disorders
Traumatic	Surgery Endoscopic/PEG complications Ventriculoperitoneal (VP) shunt VP shunt complication Sharp foreign body Erosion by battery Stab wound Blunt abdominal trauma (rare)

*Table 1: Causes of gastroduodenal perforation*

The majority is from spontaneous perforation due to peptic ulcer disease (PUD) although there are more unusual causes [1, 2]. The two main factors implicated in the etiology are non-steroidal anti-inflammatory drugs (NSAIDs) and *Helicobacter pylori* (*H. pylori*) [3, 4]. Other factors include smoking, chronic liver disease, chronic renal failure, especially during dialysis and transplantation, and hyperparathyroidism. Duodenal ulcers are four times more common than gastric ulcers below the age of 40 years and are more common in men [5, 6]. Although only 1% of gastric ulcers are pre-malignant, the percentage of cancer in gastric perforation (9%) is fairly significant [7]. Perforated peptic ulcer (PPU) despite anti-ulcer medication and *H. pylori* eradication is still the most common indication for emergency gastric surgery and associated with high morbidity and mortality. Although the surgical treatment with a simple omental patch closure of the perforation has not changed much over a century, PPU still remains a life-threatening condition with a high mortality of up to 40% [8]. Despite improvements in resuscitation techniques, antibiotic therapy and anesthesia, the mortality associated with perforated peptic ulcers has not changed over the last two decades. It remains about 25%, due to the fact that the age mix of the disease has changed with more elderly females on NSAIDs and many with serious concomitant medical illnesses (poor American society of anesthesiologist score-ASA) [9]. With the younger population in sub-Saharan Africa, the high mortality of about 20% is mostly due to the high prevalence of the causative *H. pylori*, and the late presentation and surgical treatment [10-14].

### Spontaneous perforation

Perforated peptic ulcer is an important differential diagnosis to consider in patients who are admitted with

acute abdominal pain, but only represents approximately 3% of this group of patients [7-9]. Duodenal and gastric ulcers remain the two most common perforations of the gastrointestinal tract due to the increased use of non-steroidal anti-inflammatory drugs (NSAIDs). It occurs most often in elderly patients with co-existent medical problems, who are at increased risk of post-operative complications. Benign gastric ulcers occur predominantly in the elderly, on the lesser curve. Ulcers on the greater curve, fundus and in the antrum are more commonly malignant. Gastric ulcers are less common than duodenal ulcers before age 40 years but become more common in the elderly [6-9]. Perforated gastric ulcer is much less common than perforated duodenal ulcer and the diagnosis is usually only made at the time of laparotomy. The frequency of peptic ulcer and its perforation may change depending on the frequency of *H. pylori* infection and/or age distribution. The prevalence of *H. pylori* in the low socioeconomic classes and associated poverty, overcrowding and poor hygiene have increased the incidence of duodenal and gastric perforations in all age groups particularly in the developing world [10-14]. The mean prevalence of *H. pylori* infection in patients with perforated peptic ulcer is of only about 65-70%, which contrasts with the almost 90-100% reported in non-complicated ulcer disease [4]. Recurrent ulcer disease after peptic ulcer perforation, however, mainly occurs in patients with *H. pylori* infection which suggests its important role in this complication [4, 15]. The life-time risk of benign gastroduodenal perforation is 10% in untreated PUD and, 30-50% of ulcer perforations are associated with NSAIDs [1, 2]. In this era of effective treatment of PUD with *H. pylori* eradication and proton pump inhibitors (PPIs), gastric cancer is commonly a cause of gastric outlet obstruction and perforation as opposed to peptic ulcer disease [16]. Most ulcers that perforate are sited on the anterior wall of the duodenum or stomach. The release of food and digestive enzymes into the peritoneal cavity initially causes a chemical peritonitis. Secondary bacterial peritonitis evolves later, and as with bleeding ulcers 10% of these patients will die [1, 2]. Gastric volvulus and strangulated hiatus hernia [17] can lead to perforation if all or part of the stomach wall is rendered ischemic. Although the stomach has a good blood supply, on occasions severe foregut ischemia can lead to gastric ischemia and perforation, although such patients are generally unwell before the perforation is manifest [18]. The presentation of gastric perforation is sudden onset severe epigastric pain, peritonism, a board-like abdominal rigidity caused by spasm of the recti muscles and sepsis but may be non-specific in the elderly. The perforation is usually unexpected, with no antecedent history. The peritonitis is associated with varying degrees of shock, and severe peritonitis may induce a generalized ileus [19, 20]. When posterior wall gastric ulcers perforate, they leak gastric contents into the lesser sac which tends to confine the peritonitis and present with less marked symptoms. It is important to note that there are some instances where patients do not have abdominal symptoms or signs, but chest x-rays taken for other reasons indicate a pneumoperitoneum. Perforated peptic ulcer is a common cause as the

perforation is frequently sealed by a plug of omentum or another viscus before significant soiling and peritonitis occurs [21, 22]. If perforation is in the thorax as in the case of strangulated hiatus hernia (HH), then the patient is likely to have chest symptoms and general signs of severe sepsis, with little or no evidence of peritonitis [17]. Pneumo-peritoneum on erect chest x-ray is absent in 20-30% of cases with gastric perforation, and if there is generalized peritonitis the diagnosis is confirmed at laparotomy or laparoscopy. In a relatively well patient with a sealed perforation and uncertain diagnosis, a computed tomography scan (CT) is useful [21]. The key clinical features of gastroduodenal perforation are listed in table 2.

Detailed history	Epigastric pain Drugs (NSAIDs, aspirin)
Physical examination	Abdominal guarding, rigidity Absent bowel sounds
Bloods	Leucocytosis raised CRP
Abdominal radiograph	free air under diaphragm
Oral contrast study	contrast leak in abdomen
CT scan	Free intra-peritoneal air

Table 2: Key clinical features of gastroduodenal perforation

The management of gastric perforation may be operative or non-operative. The contributory factors to either of these are the general condition of the patient, poor pre-morbid status, significant co-morbidities, and complicated pathology [2, 19, 20]. Most cases are within the remit of the general surgeon, but perforation due to strangulated HH in chest is best dealt with by a dedicated upper gastrointestinal or thoracic surgeon. The non-operative (conservative) management of perforated gastroduodenal ulcer is basically for (1) the asymptomatic (i.e. do not have generalized peritonitis or continued duodenal leak) and (2) the unfit patients [23-25]. Non-operative management has been largely abandoned even in high risk cases because the conversion to operative treatment is required in up to a third and the high incidence of intra-abdominal abscesses and sepsis [26, 27]. Operative management is encouraged by the current advances in anaesthetic approach [28].

## Operative management

### Perforated duodenal ulcer

The majority of perforated peptic ulcers are caused by *Helicobacter pylori*, so definitive surgery is not always required. However, definitive anti-ulcer surgery (parietal cell vagotomy +/- anterior linear gastrectomy) can be performed for a perforated chronic duodenal ulcer previously shown to be *H. pylori* negative or those with recurrent ulcers despite triple therapy [1, 4, 7, 12, 28]. The principle of operative management is to achieve a

quick and easy access via a formal midline laparotomy and identify the site and nature of the pathology [29, 30]. Suctioning of the gastrointestinal spillage and of any fibrinous exudates is quickly performed. This is facilitated by insinuating a hand between viscera and abdominal wall to make a space in which the sucker may be inserted, and both subphrenic spaces, the pericolic gutters and the pelvis are dealt with in turn. Attention is turned to inspection of the duodenum and visualization of the perforation. Improving access to the site of the perforation is aided by retracting the right margin of the incision and the assistant drawing the stomach and pylorus to the left by traction with a gauze swab. The perforation is usually found on the anterior wall of the duodenum, in proximity to the duodenal bulb. If the perforation is not apparent, mobilization of the duodenum along with inspection of the stomach and jejunum is carried out. With the advent of proton pump inhibitors (PPIs) and peptic ulcer association with *H. pylori*, definitive ulcer preventing operations, i.e. vagotomy or gastrectomy, have largely been abandoned [30]. The criteria for definitive ulcer operation for perforated ulcer are outlined in table 3.

- Long history of ulcer disease, especially patients under going active medical treatment
- Prior obstruction, haemorrhage or perforation
- No concurrent medical problems
- Gastric ulcers with coexistent duodenal ulcer disease
- \*Duration of perforation less than 24h
- \*Peritoneal contamination must not be extensive
- \*Patient should be haemodynamically stable

\*These criteria are essential

Table 3: Criteria for definitive ulcer operation for perforated ulcer.

Most duodenal perforations are small and easily closed. The simplest method which has amply stood the test of time is to plug the defect with a convenient frond of omentum which provides the stimulus for fibrin formation and tissue regeneration (Figure 1) [31].

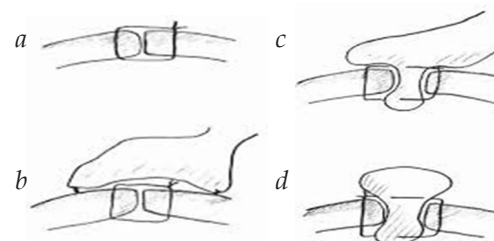


Figure 1: Summary of different suture techniques for closure of perforation (From above: (a) primary closure by interrupted sutures, (b) primary closure by interrupted sutures covered with pedicled omentopexy, (c) Cellan Jones repair-plugging the perforation with pedicled omentoplasty, (d) Graham patch-plugging the perforation with free omental plug.

Cellan-Jones in 1929 [32] suggested omentoplasty without primary closure of the defect to prevent narrowing of the duodenum. His technique consisted of placing 4-6 sutures, selecting a long omental strand and passing a fine suture through it. The tip of the strand is

then anchored in the region of the perforation and finally the sutures are tied off (Figure 1). In 1937 Graham [33] published his results with a free omental graft. He placed three sutures with a piece of free omentum laid over these sutures, which are then tied but no attempt is made to actually close the perforation (Figure 2).

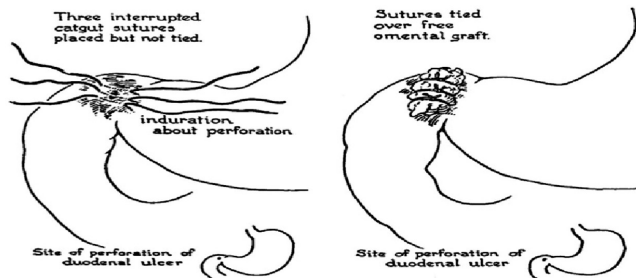


Figure 2: Omental (Graham) patch technique (plugging with non-pedicle omental flap) (with permission [34]).

Very often surgeons mention using a Graham patch, but they actually used the pedicled omental patch described by Cellan-Jones which has since been the standard of surgical repair (Figures 3, 4) [34].

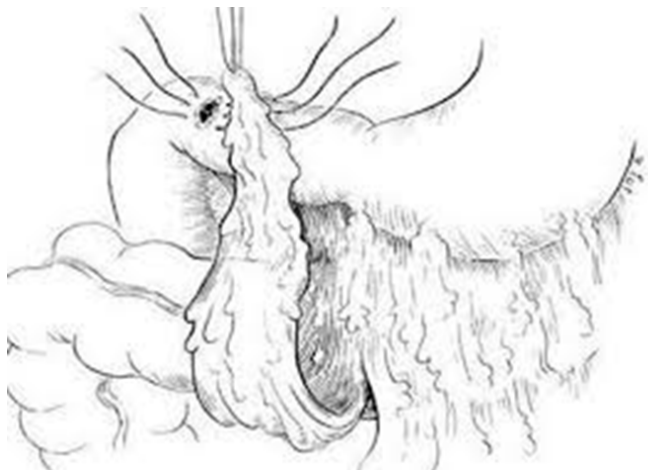


Figure 3: Pedicled omental flap repair of perforated duodenal ulcer.

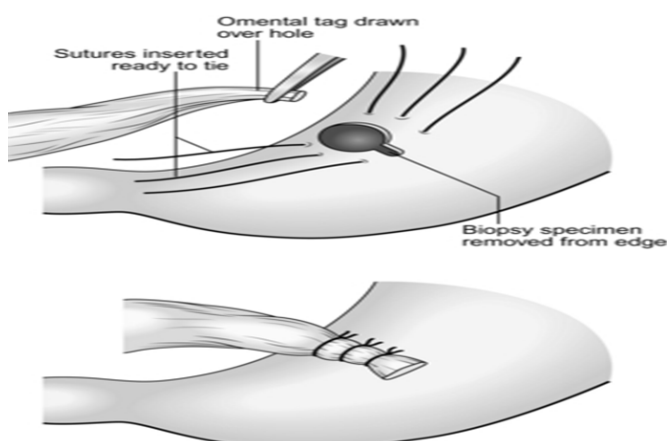


Figure 4: Pedicled omental flap repair of gastric perforation

The pedicled omental patch (Graham omentoplasty) technique entails passing through all layers of the duodenal wall using 0/0 or 2/0 absorbable vicryl on an atraumatic 30mm needle, sufficiently far from the margin of the perforation to avoid tearing out because of friability. More than three such stitches are seldom

necessary and in a small perforation, two may suffice. After placement, the sutures are left long and may be left in the tip of an artery forceps. A convenient fond of omentum with enough bulk to plug the defect is grasped in the tip of an artery forceps and drawn over the perforation to be held in place by the assistant. The stitches are then tied over the omental plug with just sufficient to retain the omental plug snugly in position. The top and bottom stitches being tied first so that tension in the middle stitch which is the most likely to cut out is reduced (Graham omentoplasty) (Figures 1, 3, 4) [32]. Simple closure of the perforation by primary closure of the defect, then application of the omental flap (modified Graham patch repair/ omentopexy) is the preferred method of dealing with perforation of less than 5mm diameter (figure 1) [29, 30, 33, 36]. Simple closure is the first treatment of choice in early presentation of < 12h of PPU and when the patient is in shock [19, 28, 36] Recent studies done in Africa continue to reveal that omentopexy or simple repair still produces good results in patients with PPU [10-14] Graham's omentoplasty (plugging) and modified Graham's omental patch repair are similarly effective repair in terms of morbidity and mortality [37-39]. However, in several occasions with larger perforations the omental plugging seems a better choice to the omental patch reinforcement technique [1, 38, 40, 41]. A recent prospective study demonstrated a figure of eight primary closure with omental flap reinforcement more superior than Graham's omentoplasty (plugging) in terms of decrease leak rate in peptic perforations less than 2cm in diameter [42]. After a thorough wash out of the peritoneal cavity with 2-3 liters of saline drainage of the peritoneal cavity is unnecessary. A routine drain insertion is unproven [43-46]. A drain will not reduce the incidence of intra-abdominal fluid collections or abscesses [44]. On the other hand, the drain site can become infected (10%) and can cause intestinal obstruction [45]. In case of suspected leakage, a CT scan will provide all the information needed, probably better than a non-productive drain [46]. The possible criticism that midline incisions are prone to dehiscence and herniation is answered by the use of the Jenkin's mass closure technique [47]. Although operative management of a perforated duodenal ulcer (usually anterior D1) is generally straightforward, with an omental patch being fashioned after peritoneal lavage, Kocher's maneuver to mobilize the duodenum is performed if access to the duodenum is poor. A large perforation may lead to duodenum appearing to disintegrate and if it cannot be patched then it must be resected. Various methods are described to deal with this difficult duodenum [48]. Finney pyloroplasty involves fully Kocherizing the duodenum and opening it longitudinally along most of its length and then closed transversely in a similar fashion to simple pyloroplasty. More often, if the duodenal ulcer is too large and/or the tissues are too friable to perform a simple closure, a partial gastrectomy may be required. It may be necessary in some cases to exclude or excise the ulcer, close the duodenum distally, and excise the gastric antrum resulting to a Billroth II resection [48-50]. If no perforation site is evident on initial laparotomy, the posterior surface of the stomach is exposed in the lesser sac. Infrequently

perforation and hemorrhage from an anterior ulcer may coexist, and, partial gastrectomy of the Billroth II (Kronlein-Polya) type is advisable [45]. *H. pylori* is the most important factor for ulcer recurrence following operative repair of perforated duodenal ulcer and merits eradication along with PPI therapy for about 4-6 weeks. Confirmation of eradication with Urea breath test is recommended in patients with resistant ulcer, MALT lymphoma and previous resection of gastric cancer [1, 4].

### **Perforated gastric ulcer**

A perforated gastric ulcer needs careful assessment. A proportion (9%) will be malignant [7] and gastric ulcers are more likely to re-perforate after simple closure with high mortality (15%) [7]. Tissue biopsies from the edge of the ulcer are taken because of the risk of malignancy, even in a benign-looking condition [1, 28, 51]. The closure with an omental patch and *H. pylori* eradication as in duodenal perforation is feasible in distal or pre-pyloric ulceration as such ulcers are akin to duodenal ulcers [1, 28]. Ulcer excision with post operative PPIs, allows closure of 'healthy' gastric tissue, as well as providing histology, but, a distal gastrectomy with gastroduodenal anastomosis (Billroth I) should be considered if closure is difficult, the patient is sufficiently fit and the surgeon sufficiently experienced. Chung et al [52] noted that less than 10% of PPU patients required gastric resection and with a mortality risk of 24 % the outcome was more inferior than omental patch repair. Follow-up endoscopy with repeat biopsy is still essential to avoid missing an underlying malignancy [1, 7, 53]. In the pre-*H. pylori* eradication era, 80% of patients with simple omental closure alone developed recurrent ulcers. The mortality after surgery for PPU is between 6 and 19% [7, 10-14, 54]. The four main factors which severely increase the mortality rate are a) age >60 yrs, (b) delayed treatment (>24hrs), shock on admission (systolic BP < 100mmHg) and concomitant diseases including HIV/AIDS (CD4 count <200 cells/ul [10-14, 53, 55]. Gastric ulcers are associated with a two to three-fold increased mortality risk [56, 57]. Mortality is three to four-fold higher in the elderly (up to 50%), due to occurrence of concomitant medical diseases and difficulty in making the right diagnosis resulting in delay of treatment [7, 58]. Factors such as shock on admission or delayed surgery were associated with omental patch leakage with increased mortality [59]. The size of the opening may also determine the extent of the peritoneal contamination and adversely affects the prognosis. If the perforation is less than 5mm in diameter there is a 6% mortality rate, when it is between 5 and 10mm, the mortality is 19% and when it is more than 10mm the mortality rate is around 24% [60]. The choice of operative technique will depend on the position and size of the ulcer and the age and fitness of the patient. Perforated pre-pyloric ulcers are treated similarly to perforated DU, but more proximal gastric ulcers are best resected where possible [61]. If it is likely to lead to significant stenosis, then a patch repair can be performed (Figure 4). On some occasions it may be best to proceed with partial gastrectomy. Even in cases of benign ulceration with perforation where tissue is edematous and swollen and have appearances

of a neoplasm, decision to resect is difficult in these usually unstable patients. If any doubt as to how to proceed, immediate patient safety must come first, with peritoneal lavage and drainage as priority [51]. Postoperative complications following repair of gastric ulcer perforation include intraperitoneal abscess in the subphrenic space or pelvis, persistence or recurrence of ulcer symptoms especially if post-operative *H. pylori* eradication was avoided, leakage from oversewn perforation and re-perforation, and gastric outlet obstruction from scarring of the duodenum [7].

### **Is there a role for Laparoscopic surgery in perforated peptic ulcer disease?**

Laparoscopic treatment of peptic ulcer perforation was first reported in 1990 [62] and suggest that laparoscopically performed omental patching is feasible and safe and has comparable results to open surgery and with less postoperative discomfort [63-66]. Laparoscopic repair using the easily mobilized falciform ligament for patch closure is a reasonable option in selected patients with a history of less than 24 h, no evidence of hypovolemic shock, and with a perforation of < 8-10mm [67-69]. However, practice depends on expertise and local availability of laparoscopic surgery [28]. A meta-analysis showed 85% success in the laparoscopic approach with a reduced wound infection, and pain [70]. However, there was an increase rate of re-operation for leakage. This may be due to difficulty in the laparoscopic suturing procedure and the learning curve required. Thus, the need for a laparoscopically trained surgeon to perform the procedure [71]. The mortality and morbidity are comparable in published series for open vs laparoscopic approach, but there have been no large randomized clinical trials [72] comparing one against the other [72, 73]. Other methods include sutureless techniques involving the use of gelatin sponge plug with fibrin glue sealing or the use of endoscopic clipping techniques, but the complication and mortality rates are quite high limiting their use [74-77]. Following the repair, peritoneal washout with several liters of warm saline would prevent interloop and intra-abdominal abscesses [78, 79]. A minimally-invasive alternative is the insertion of self-expandable metal stents and drainage. This is one of the new treatment options for PPU which can be used primarily or secondarily to deal with post operative leakage after surgical closure. A study involving 10 patients with PPU showed good clinical results [80].

### **Perforated stomal ulcers**

Perforated stomal ulcers are usually managed with omental patch [81]. The usual anatomy will be distorted by the presence of either an antecolic, retrocolic gastroenterostomy or a Roux-en Y anastomosis. An antecolic gastroenterostomy is relatively easy to find as there will be a loop of small bowel anterior to the transverse colon to the stoma but a retrocolic gastroenterostomy may not be immediately apparent as it lies deep to the transverse colon and omentum.

### **Perforated hiatus hernias / gastric volvulus / acute**

## gastric dilatation

Perforated hiatus hernia or gastric volvulus, when part or all of the stomach is in the chest, present extremely difficult scenarios. Surgery in this situation may require thoracotomy, resection, and then a decision made regarding primary or delayed reconstruction [17, 18]. The influencing factors are the time since presentation, degree of mediastinal and pleural soiling, and the general condition of the patient [17, 18, 82]. It is important to remember that acute gastric dilatation is a common postoperative complication of major upper abdominal surgery although it is commonly seen in trauma, post splenectomy and with the gastric autonomic neuropathy of diabetes mellitus. It may cause gastric perforation amenable to primary closure [83-85]. From the author's experience, the subtle presentation of left shoulder tip pain and hiccups from diaphragmatic irritation may lead to it being unrecognized and untreated with a fatal outcome due to vomiting and aspiration. The correction of any biochemical abnormalities, such as potassium is essential, and the treatment is by large bore nasogastric (NG) tube with regular aspiration [86].

## Conclusions

The majority of gastric perforations are spontaneous from peptic ulcer disease and the management is still a subject of debate. Perforated peptic ulcer (PPU) despite anti-ulcer medication and *H. pylori* eradication is still the most common indication for emergency gastric surgery and associated with high morbidity and mortality. Surgical techniques are varied, but laparotomy and omental patch repair remains the gold standard while laparoscopic surgery should only be considered when expertise is available. This must be followed by *H. pylori* eradication therapy to prevent recurrence.

## Acknowledgements

None

## Contributors

EPW conceptualized and designed the study, acquired, and analyzed data, interpreted the study results, drafted and revised the manuscript.

## Funding

No funding was received for this study.

## Competing interests

No benefits in any form have been received or will be received from a commercial party related directly or indirectly to the subject of this article.

## Availability of data and materials

Further information is available from the corresponding author on reasonable request.

## Ethics approval

Not applicable

## Provenance and peer review

Not commissioned; externally peer reviewed.

## Open access

This is an Open Access article distributed in accordance with the Creative Commons Attribution Non-Commercial (CC BY-NC 4.0) license, which permits others to distribute, remix, adapt, build upon this work noncommercially, and license their derivative works on different terms, provided

the original work is properly cited and the use is non-commercial. See: <http://creativecommons.org/licenses/by-nc/4.0/>

## References

- [1] Bertleff MJ, Lange JF. Perforated peptic ulcer disease: a review of history and treatment. *Dig Surg* 2010;27:161-169
- [2] Lau JY, Sung J, Hill C, Henderson C, Howden CW, Metz DC. Systematic review of the epidemiology of complicated peptic ulcer disease: incidence, recurrence, risk factors and mortality. *Digestion*. 2011;84:102-113
- [3] Garcia Rodriguez LA, Barreales Tolosa L. Risk of upper gastrointestinal perforations among users of traditional NSAIDs and COXIBS in the general population. *Gastroenterology*. 2007; 132:498-506
- [4] Gisbert JP, Pajares JM. *Helicobacter pylori* infection and perforated peptic ulcer prevalence of the infection and role of antimicrobial treatment. *Helicobacter*. 2003; 8: 159-167
- [5] Kurata JH, Haile BM. Epidemiology of peptic ulcer disease. *Clin Gastroenterol* 1984;13(2): 289-307
- [6] Janik J, Chwirot P. Perforated peptic ulcer-time trends and patterns over 20 years. *Med Sci Monit*. 2000;6:369-372
- [7] Leeman MF, Skouras C, Paterson-Brown S. The management of perforated gastric ulcers. *Int J Surg* 2013;11(4):322-344
- [8] Thorsen K, Glomsaker TB, Von Meer A, et al. Trends in diagnosis and surgical management of patients with perforated peptic ulcer. *J Gastrointest Surg* 2011;15:1329-1335
- [9] Irvin TT. Mortality and perforated peptic ulcer: a case for risk stratification in elderly patients. *Br J Surg* 1989;76:215-18
- [10] Rickard J. Surgery for peptic ulcer disease in sub-Saharan-Africa: Systematic review of published data. *J. Gastrointest Surg* 2016;20(4):840-50
- [11] Chalya PL, Mabula JB, Koy M, McHembe MD, Jaka HM, Kabangila R, et al. Clinical profile and outcome of surgical treatment of perforated peptic ulcers in Northwestern Tanzania: A tertiary hospital experience. *World J Emerg Surg* 2011;6:31
- [12] Alegbeleye BJ. A modified open omental plugging of peptic ulcer perforation in a mission hospital, North Western Cameroon. *J. Clin Invest Stud* 2019;2.
- [13] Bekele A, Zemenfes D, Kassa S, et al. Patterns and seasonal variations of perforated peptic ulcer disease: Experience from Ethiopia. *Ann Afr Surg* 2017;14(2):86-91
- [14] Dongo AE, Uhunmwagho O, Kesieme EB, et al. A five - year review of perforated peptic ulcer disease in Imira, Nigeria. *Int Sch Res Notices* 2017:82375398
- [15] Ng EK, Lam YH, Sung JJ, Yung MY, To KF, Chan AC, et al. Eradication of *Helicobacter pylori* prevents recurrence of ulcer after simple closure of duodenal ulcer perforation: randomized controlled trial. *Ann Surg*. 2000;231:153-158
- [16] Weledji EP, Enworock G, Ngowe MN. Gastric leiomyosarcoma as a rare cause of gastric outlet obstruction and perforation: a case report. *BMC Res Notes* 2014;7:479
- [17] Imperatore K, Olivieri B, Vincentelli C. Acute gastric volvulus: a deadly but commonly forgotten complication of hiatal hernia. *Autops Case Rep*.2016;6(1): 21-26
- [18] Lundsmith E, Zheng M, McCue P, Niu B. Chronic gastric ischaemia leading to gastric perforation. *ACG Case Rep J*. 2016;3(4):e194
- [19] Simon Paterson-Brown. Diagnosis and investigation in the acute abdomen. In: *Emergency Surgery and critical care. A companion to specialist surgical practice.* Simon Paterson-Brown (ed) 2000. W.B. Saunders company
- [20] Stoddard CJ. Common abdominal emergencies: Acute perforations. *Surgery*2000:13-17
- [21] Grassi R, Romano S, Pinto A, Romano L. Gastro-duodenal perforations: conventional plain film, US and CT findings in 166 consecutive patients. *Eur j Radiol*.2004;50:30-36
- [22] Bas G, Eryilmaz R, Okan I, Sahin M. Risk factors of morbidity and mortality in patients with perforated peptic ulcer. *Acta Chir Belg*, 2008; 108:424-427
- [23] Songne B, Jean F, Foulatier O, Khalil H, Scotte M. Non-operative treatment for perforated peptic ulcer: results of a prospective study. *Ann Chir*.2004:129:578-582
- [24] Bucher P, Oulhaci W, Morel P, Ris F, Huber O. Results

of conservative treatment for perforated gastroduodenal ulcers in patients not eligible for surgical repair. *Swiss Med Wkly.* 2007;137:333-340

[25] Donovan AJ, Berne TV, Donovan JA. Perforated duodenal ulcer: an alternative therapeutic plan. *Arch Surg.*1998;133:1161-1171

[26] Crofts TJ, Park KG, Steele RJ, Chung SS, Li AK. A randomized trial of non-operative treatment for perforated peptic ulcer. *N Engl J Med.* 1989;320:970-973

[27] Anbalakan K, Chua D, Pandya GY, Shelat VG. Five year experience in management of perforated peptic ulcer and validation of common mortality risk prediction models-are existing models sufficient? A retrospective cohort study. *Int J Surg.*2015;14:38-44

[28] Zittel TT, Jehl EC, Becker HD. Surgical management of peptic ulcer disease today- indication, technique and outcome. *Langenbecks Arch Surg.* 2000; 385:84-96

[29] Soreide K, Thorsen K, Soreide JA. Strategies to improve the outcome of emergency surgery for perforated peptic ulcer. *Br J surg.* 2014;101:e51-e56

[30] Lau WY, Leow CK. History of perforated duodenal and gastric ulcers. *World J Surgery.* 1997; 21:890- 896

[31] Di Nicola V. Omentum a powerful biological source in regenerative surgery. *Regenerative therapy* 2019;11:182-191

[32] Cellan-Jones CJ: A rapid method of treatment in perforated duodenal ulcer. *BMJ* 1929;1076-1077.

[33] Graham RR. The treatment of perforated duodenal ulcers. *Surg Gynec Obstet* 1937;64: 235-238

[34] Fallat ME, White MJ, Richardson JD, Flint LM: Reassessment of Graham-Steele closure in acute perforated peptic ulcer. *South Med J* 1983;76:1222-1224.

[35] Bornman PC, Theodorou Na, Jeffery PC, Marks IN, Essel HP, Wrght JP, Terblanche J. Simple closure of perforated duodenal ulcer: a prospective evaluation of a conservative management policy. *Br J Surg.*1990;77:73-75

[36] Raimes SA, Devlin HB. Perforated duodenal ulcer. *Br J Surg* 1987; 74-81

[37] Arora BK, Arora R, Arora A. Modified Graham's repair for peptic ulcer perforation: reassessment study. *Int Surg J* 2017;4(5): 1667-1671

[38] Abdallah HA, Saleem AEA. Comparative study between Graham's omentopexy and modified Graham's omentopexy in treatment of perforated duodenal ulcers. *Egypt J Surg* 2018;37: 485-9.

[39] Kidwai R, Ansari M. Graham patch versus modified Graham patch in the management of perforated duodenal ulcer *J of Nepalgunj Med Coll* 2015;13

[40] Jani K, Saxena AK. Management of large sized duodenal peptic perforations by omental plugging- a new technique: a prospective randomized study of 100 patients. *Indian J Surg.* 2000;62:134-138

[41] Mukhopadhyay M, Banerjee C, Sarkar S, Roy D, Rahman QM. Comparative study between omentopexy and omental plugging in treatment of giant peptic perforation. *Indian J Surg* 2011;73(5):341-346

[42] Vichyarthi SH, Jangir MK, Singh A. A prospective study for comparison between Graham's omentopexy versus figure of eight closures in cases of peptic perforation. *Int J Surg Sc* 2020;4(2): 142-145

[43] Schein M. To drain or not to drain? The role of drainage in the contaminated and infected abdomen: an international and personal perspective. *World J Surg* 2008;32:312-321

[44] Pai D, Sharma A, Kanungo P, Jagdish S, Gupta A. Role of abdominal drains in perforated duodenal ulcer patients: a prospective controlled study. *Aust N Z J Surg.* 1999;69:210-213

[45] Schein M: To drain or not to drain? The role of drainage in the contaminated and infected abdomen: an international and personal perspective. *World J Surg* 2008;32:312-321.

[46] Weledji EP, Ngowe NM. The challenge of intraabdominal sepsis. *Int J Surg (Lond)* 2013;11:290-295

[47] Jenkins TPN. The burst abdominal wound: a mechanical approach. *Br J Surgery* 1976;63:873-876

[48] Gupta S, Kaushik P, Sharma R, Attri A. The management of large perforations of duodenal ulcers. *BMC Surg.*2005; 5:15.

[49] Schein M: Perforated peptic ulcer; in (ed.): Schein's Common Sense Emergency Abdominal Surgery. Part III. Berlin, Springer, 2005, pp 143-150.

[50] Kuwabara K, Matsuda S, Fushimi K, Ishikawa KB, Horiguchi H, Fujimori K. Reappraising the surgical approach on the perforated gastroduodenal ulcer: should gastric resection be abandoned? *J Clin Med Res.*2011;3: 213-222

[51] Ignjatovic N, Stojanov D, Djordjevic M, Ignjatovic J, Stojanov B, Milojkovic B. Perforation of gastric cancer-what should the surgeon do? *Bosn J Basic Med Sci* 2016;16(3):222-226

[52] Chung KT, Shelat VG. Perforated Peptic Ulcer- An update. *World J Gastrointestinal Surg* 2017;8(1):1-127;14(2):86-91

[53] Tan KK, Quek JT, Wong N, Li KK, Lim KH. Emergency surgery for perforated gastric malignancy: an institution's experience

and review of the literature. *J. Gastrointest Oncol* 2011;2(1); 13-18

[54] Imhof M, Epstein S, Ohmann C, Roher HD: Duration of survival after peptic ulcer perforation. *World J Surg* 2008;32:408-412.

[55] Weledji EP, Nsagha D, Chichom A, Enoworock G. Gastrointestinal surgery and the acquired immune deficiency syndrome. *Ann Med Surg (Lond)* 2015; 4: 36-40

[56] Zittel TT, Jehle EC, Becker HD: Surgical management of peptic ulcer disease today: indication, technique and outcome. *Langenbecks Arch Surg* 2000;385:84-96.

[57] Harbison SP, Dempsey DT: Peptic ulcer disease. *Curr Probl Surg* 2005;42:346-454.

[58] Feliciano DV, Bitondo CG, Burch JM, Mattox KL, Jordan GL Jr, DeBakey ME: Emergency management of perforated peptic ulcers in the elderly patient. *Am J Surg* 1984; 148:764-767.

[59] Maghsoudi H, Ghaffari A. generalized peritonitis requiring re-operation after leakage of omental patch repair of perforated peptic ulcer. *Saudi J Gastroenterol* 2011;17:124-8

[60] Hennessy E. Perforated peptic ulcer mortality and morbidity in 603 cases. *Aust NZ J Surg.* 1969;38:243

[61] Sarosi GA Jr, Jaiswal KR, Nwariaku FE, Asolati M, Fleming JB, Anthony T: Surgical therapy of peptic ulcers in the 21st century: more common than you think. *Am J Surg* 2005; 190:775-779

[62] P, Francois Y, Vignal J, Barth X, Lombard -Platelet R. Laparoscopic treatment of perforated peptic ulcer. *Br J Surg.*1990;77:1006

[63] Miserez M, Eypasch E, Spangenberg W, Lefring R, Troird H. Laparoscopic and conventional closure of perforated peptic ulcer- a comparison. *Surg Endosc Ultrasound Intervent Techniques* 1996;10:831-6

[64] Abd Ellatif ME, Salama AT, Elezaby AF, El-Kaffas HT, Hassan A, Magdy A, Abdullah E, El-Morsy G. Laparoscopic repair of perforated peptic ulcer: patch versus simple closure. *Int J Surg(Lod)* 2013;11:948-951

[65] Song KY, Kim TH, Kim SN, Park CH. Laparoscopic repair of perforated duodenal ulcers: the simple "one-stitch" suture with omental patch technique. *Surg Endosc.* 2008;22:1632-1635

[66] Vaccari S, Andrea VD, lauro A, D'Intino R. Gulotta E, Cervellera M, Tonini V. Laparoscopic repair for perforated peptic ulcer: our experience, a comparison with the open approach and a review of the literature. *J of gastric Surgery* 2020;2(2)

[67] Kim JH, Chin HM, Bae YJ, Jun KH. Risk factors associated with conversion of laparoscopic simple closure in perforated duodenal ulcer. *Int J Surg* 2015;15:40-44

[68] Shelat VG, Ahmed S, Chia CL, Cheah YL. Strict selection criteria during surgical training ensures good outcome in laparoscopic omental patch repair (LOPR) for perforated peptic ulcer (PPU). *Int Surg*2015;100:370-375

[69] Lee FY, Leung KL, Lai PB, Lau JW. Selection of patients for laparoscopic repair of perforated peptic ulcer. *Br J Surg.*2001;88:133-136

[70] Sanabria A, Villegas MI, Morales Uribe CH. Laparoscopic repair for perforated peptic ulcer disease. *Cochrane database Syst Rev.*2013;2:CD004778

[71] Lau H. Laparoscopic repair of perforated peptic ulcer: a meta-analysis. *Surg endosc.*2004;18:1013-1021

[72] Bertleff MJ, Halm JA, Bemelman WA, van de Ham AC, van der Harst E, Oei HL, et al. Randomized clinical trial of laparoscopic versus open repair of the perforated peptic ulcer: the LAMA Trial. *World J Surg* 2009; 33:1368-1373

[73] Lunevicius R, Morevicius M. Systematic review comparing laparoscopic and open repair of perforated peptic ulcer. *Br J Surg* 2005;92:1195-1207

[74] Wang YC, Hsich CH, Lo HC, Su LT. Sutureless onlay omental patch for the laparoscopic repair of perforated peptic ulcers. *World J Surg* 2014;38:1971-1921.

[75] Lagoo S, McMahon RL, Kakihara M, et al. the sixth decision regarding perforated duodenal ulcer. *JCLS* 2002;6:359-368.

[76] Ishiguro T, Nagawa H. Inadvertent endoscopic application of hemoclip to the splenic artery through a perforated gastric ulcer. *Gastrointest Endosc* 2001;53:378-379.

[77] Hashiba K, Carvalho AM, Dinz G, et al. Experimental endoscopic repair of gastric perforations with an omental patch and clips. *Gastrointest Endosc* 2001;54: 500-4.

[78] Whiteside OJ, Tytherleigh MG, Thrush S, Farouk R, Galland RB. Intra-operative peritoneal lavage- who does it and why? *Ann R Coll Surg Engl.*2005;87:255-258

[79] Schein M, Gecelter G, Freinkel W, Gerding H, Becker PJ. Peritoneal lavage in abdominal sepsis. A controlled clinical study . *Arch surg* 1990;125:1132-1135

[80] Bergstrom M, Arroyo Vasquez JA, Nsouli G, et al. Good results of stent treatment in perforated duodenal ulcer. *Lakartidningen* 2015;112]

[81] Kalaiselvan P, Exardos G, Hamza N, Amniois BJ. Incidence of perforated gastrojejunal anastomotic ulcers after laparoscopic gastric bypass for morbid obesity and role of laparoscopy in their

management. *Surg Obes Relat Dis* 2012; 8(4):423-428

[82] Sutcliffe RP, Forchaw MJ, Datta G, Rohatgi A, Strauss DC, Mason RC, Botha AJ. Surgical management of Boerhave's syndrome in a tertiary oesophagogastric centre. *Ann R Coll Surg Engl* 2009;91(5):374-80

[83] Rodriguez-Jacobo S, Jacobo-Karam JS, Valencia-Perez G. Acute gastric dilation after trauma. *Clin Image in gastroenterol* 2016;81:1

[84] Weledji EP. Benefits and risks of splenectomy. *Int J Surg (Lond)* 2014;12:113-119

[85] Jung SU, Lee SH, Ahn BK, Baek SU. Gastric perforation caused by acute massive gastric dilatation: Report of a case. *J Med cases* 2012;3(5): 286-289

[86] Sahoo MR, Kumar AT, Jaiswal S, Bhujabai SN. Acute dilatation, ischaemia, and necrosis of stomach without perforation. *Case Repot in Surg* 2013; 984594